

Laparoscopic Management of Undescended Testis

¹Sarvepalli Sudhakar, ²Balachandran Premkumar

¹General Surgery-registrar, ²Consultant General and Laparoscopic Surgeon, Apollo Hospitals, Chennai

Abstract: A 28-year-old male was identified to have a right sided undescended testis, on his master health check-up. Ultrasound examination identified the testis to be in the inguinal canal near the deep ring. The patient was counseled of the consequences of undescended testis in the adult and after obtaining his fully informed consent he underwent a laparoscopic right orchidectomy and mesh repair.

This article highlights the consequences of undescended testis, the various modalities of investigation, treatment and also emphasizes on the role of laparoscopy in its management.

Keywords: Undescended testis, cryptorchidism, orchidectomy, laparoscopy.

CASE REPORT

A young software engineer attended the master health check-up as his pre-employment requirement. His clinical examination found the absence of the right testicle. He was not aware that he had a problem, and mentioned that his condition was present from birth. He was completely evaluated and his left testicle was found to be normal. An ultrasound examination confirmed an empty right scrotum with presence of the right testicle with 'altered echotexture' in the right inguinal canal near the deep ring (Fig. 1).

The patient was counseled and informed consent for surgery was obtained. He underwent a laparoscopic right orchidectomy and mesh repair. During surgery his right iliac nodes were found to be enlarged which were removed and sent for histopathological examination.

His postoperative period was uneventful and he was discharged on the first postoperative day. His sutures were removed on the tenth postoperative day.

The histopathological findings of the testis were consistent with cryptorchid testis, while the lymph nodes showed only reactive changes.

The patient was advised to carry on routine activities and have an abdominal ultrasound once a year as follow-up.

OPERATIVE STEPS

Under general anesthesia, the patient was placed in the supine position. The theatre set-up was as shown in the Figure 2.

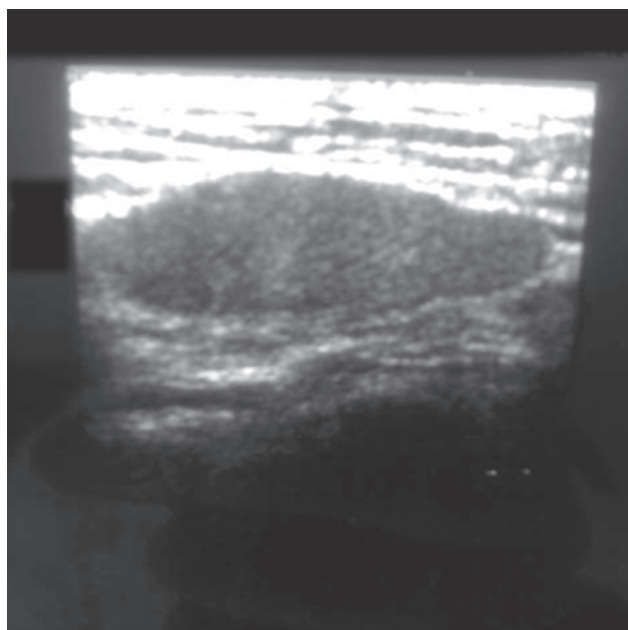


Fig. 1: Ultrasound showing testis in right inguinal canal

The trocars were placed as follows:

- 10 mm—umbilical—camera port.
- 5 mm—right lumbar—right hand working.
- 5 mm—left lumbar—left hand working.

On entry into the peritoneal cavity a thorough inspection of all the viscera was done. The peritoneum over the right inguinal region was dissected and the spermatic cord was identified entering into the deep ring. Traction was applied to the cord and the testis was delivered into the peritoneal cavity. The cord was ligated and the testis was cut and extracted through an extended umbilical port. A few enlarged lymph nodes were found along the right iliac vessels which were removed and sent for histopathology. As the right inguinal canal was empty a mesh repair using prolene mesh was done and anchored with tackers. The peritoneum was closed over the mesh using tackers. Pneumoperitoneum was reduced and the ports were closed with 1° Vicryl; and 3°0 Monocryl.

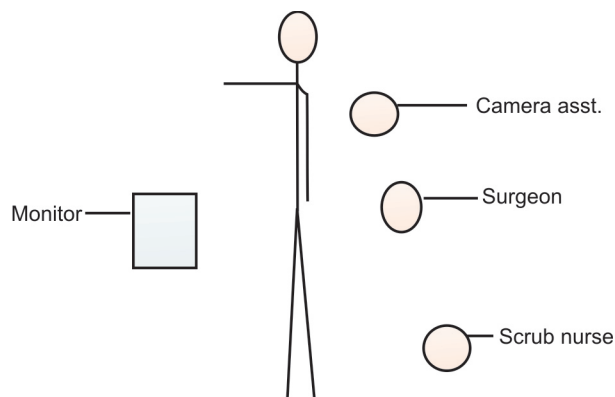


Fig. 2: Setup in the operation theatre

DISCUSSION

Most undescended testicles are present at birth. True undescended testicles rarely descend spontaneously after three months of age. Through surgical examination, about one half of nonpalpable testes are found to be intra-abdominal, while the rest represent absent (vanishing) or atrophic testes. The vanishing testicle is thought to be caused by intrauterine testicular torsion.¹¹

Underlying reasons for cryptorchidism, such as Prader-Willi, Kallmann's or Laurence-Moon-Biedl syndromes should be looked for in these patients. The genitalia should be examined for evidence of hypospadias or ambiguity. Concurrence of hypospadias and undescended testis is commonly associated with states of intersexuality,⁹ especially mixed gonadal dysgenesis and true hermaphroditism.¹⁰

Treatment for the undescended testis is recommended as early as six months of age and should be completed before age two.¹ Orchidopexy should be done either as a single or multi staged procedure, and the testis should be brought down into the scrotum. In adults orchidopexy and scrotal placement of the testis gives cosmetic satisfaction to the patient and also maintains steroid hormonogenesis. However, the patient should be counseled on the importance of repeated self examination as the incidence of malignancy in these testicles is higher. If one testis is normal and functioning well the option of orchidectomy can be given to the patient to avoid the problem of these examinations.

CLASSIFICATION OF UNDESCENDED TESTIS

1. True undescended testicles (including intra-abdominal, peeping at the internal ring and canalicular testes), which exist along the normal path of descent and have a normally inserted gubernaculum.
2. Ectopic testicles, which have an abnormal gubernacular insertion.
3. Retractable testicles, which are not truly undescended.

CONSEQUENCES OF UNDESCENDED TESTIS

Testicular neoplasm, subfertility, testicular torsion and inguinal hernia are the known and documented consequences. Of the neoplasms, testicular germ cell cancers are usually seen. The incidence among men with an undescended testicle is approximately one in 1,000 to one in 2,500.⁷

Such individuals are found to have lower sperm counts, poorer quality sperm and lower fertility rates than men whose testicles descended normally. The likelihood of subfertility increases with bilateral involvement and increasing age at the time of orchiopexy.

The incidence of testicular torsion is thought to be higher in undescended testes than in normal scrotal testes. Torsion of an undescended testicle often occurs with the development of a testicular tumor, presumably caused by increased weight and distortion of the normal dimensions of the organ. Torsion of an intra-abdominal testicle may present as an acute abdomen.¹⁰

Most true cases of undescended testicles are associated with a patent processus vaginalis. A man with an untreated, undescended testicle and an occult inguinal hernia may present at any time with symptoms and complications typical of any inguinal hernia.⁷

HORMONAL THERAPY

Human chorionic gonadotropin (HCG) is used and is administered intramuscularly. However, the likelihood of success is greatest in the most distal true undescended testicles. In theory, an ectopic testis should not respond to hormone therapy because it is physically prevented from descending. A high undescended testis is unlikely to descend completely; if it does, it will probably ascend after the hormone stimulation is withdrawn. Some side effects of hCG administration can be disturbing for parents. These include enlargement of the penis, pubic hair growth, increased testicular size and aggressive behavior during administration. Studies suggest that gonadotropin-releasing hormone (GnRH) is more effective than HCG in achieving testicular descent.⁸

ROLE OF LAPAROSCOPY

It is diagnostic and potentially therapeutic.³ Initially, it is important to determine whether a testis exists. If the absence of a testis is surgically confirmed by identifying blind-ending testicular vessels, the surgery should be terminated. Sometimes, the testicular vessels are traced to an abdominal, inguinal or scrotal testicular remnant, which is then removed. In about one half of cases, an intra-abdominal testis is found which is either brought to the scrotum or removed.¹²

After performing a diagnostic laparoscopy, the inguinal rings are examined, and the status of the processus vaginalis (patent or non-patent), wolffian structures and testicular vessels can be easily identified.² The presence of blind-ending spermatic

vessels confirms an absent testis, allowing termination of the procedure without a groin incision. If vessels and vas deferens exit the internal ring, the groin can be explored. If an intra-abdominal testis is identified, the physician can then choose the best surgical approach.¹²

Laparoscopy is the modality of choice for cryptorchid children.¹³ In majority of adult patients cryptorchid testis is intra-abdominal either at the deep ring or high intra-abdominally. Laparoscopy obviates the need of unnecessary inguinal exploration and disrupting normal inguinal canal mechanism. If attenuated testicular vessels are noted entering inguinal canal, then inguinal exploration is indicated. However, in cases of blind ending vas, when there is no inguinal hernia, laparoscopy can be safely used with the deep ring occluding mesh plug.⁴

CONCLUSION

Laparoscopy remains the modality of choice in the diagnosis and surgical management of adult cryptorchidism.¹² Its minimal invasiveness combined with excellent imaging obviates the need for costly investigations like MRI and CT scan and prevents unnecessary inguinal exploration and laparotomy.^{5, 6}

REFERENCES

1. Colodny AH. Undescended testes—is surgery necessary? [Editorial]. *N Engl J Med* 1986;314:510-1.
2. Cortesi N, Ferrari P, Zambarda E, Manenti A, Baldini A, Morano FP. Diagnosis of bilateral abdominal cryptorchidism by laparoscopy. *Endoscopy* 1976;8:33-4.
3. Deans GT, O'Reilly PH, Brough WA. Laparoscopy for undescended testis: embryological considerations. *Br J Urol* 1995;76:806-7.
4. Desai CS, Prabhu RY, Supe AN. 25-6, 48, 2002, JPGM.
5. Docimo S. Improved technique for open laparoscopic access. *J Endourol* 1998;12:S185.
6. Lojanapiwat B, Soonthornpun S, Wudhikarn S. Preoperative laparoscopy in the management of the nonpalpable testis. *J Med Assoc Thai* 1999;82:1106-10.
7. Pinczowski D, McLaughlin JK, Lackgren G, Adami HO, Persson I. Occurrence of testicular cancer in patients operated on for cryptorchidism and inguinal hernia. *J Urol* 1991;146:1291-4.
8. Pyorala S, Huttunen NP, Uhari M. A review and meta-analysis of hormonal treatment of cryptorchidism. *J Clin Endocrinol Metab* 1995;80:2795-9.
9. Rajfer J, Walsh PC. The incidence of intersexuality in patients with hypospadias and cryptorchidism. *J Urol* 1976;116:769-70.
10. Riegler HC. Torsion of intra-abdominal testis: an unusual problem in diagnosis of the acute surgical abdomen. *Surg Clin North Am* 1972;52:371-4.
11. Schultz KE, Walker J. Testicular torsion in undescended testes. *Ann Emerg Med* 1984;13:567-9.
12. Sexton WJ, Assimios DG. Diagnostic and therapeutic laparoscopy for the adult cryptorchid testicle. *Tech Urol* 1999;5:24-8.
13. Silver RI, Docimo SG. Cryptorchidism. In Gonzales ET, Bauer SB, (Eds): *Pediatric urology practice*. Philadelphia: Lippincott-Raven, 1999;499.